

Small

A FELINE INFECTIOUS PERITONITIS TREATMENT PROTOCOL

David Hughes (BSC BVSc Merit) &
Rebecca Brady (BVSc Merit)

Concord Veterinary Hospital

191 Concord Road

North Strathfield NSW 2137

t. +61 2 9743 1715

e. concordvets@concordvets.com.au

www.concordvets.com.au

C&T No. 5896



David Hughes graduated from the University of Sydney in 2010 and became a practice owner in 2013 at Concord Veterinary Hospital. The hospital has a solid historical affiliation with The Cat Protection

Society of NSW, providing a high feline case load. David and his team have developed an interest in canine and feline internal medicine and ophthalmology. They have so far treated over 20 feline infectious peritonitis cases utilising this constantly evolving protocol.



Rebecca Brady graduated from the University of Sydney in 2012 and immediately went into co-ownership of Concord Veterinary Hospital with David Hughes. She has a strong passion for feline internal

medicine, behavioural medicine and feline welfare. She has gained a keen interest in feline imaging—especially abdominal ultrasound. She finds shelter medicine particularly rewarding which is strengthened by Concord Veterinary Hospital's strong association with The Cat Protection Society of NSW.

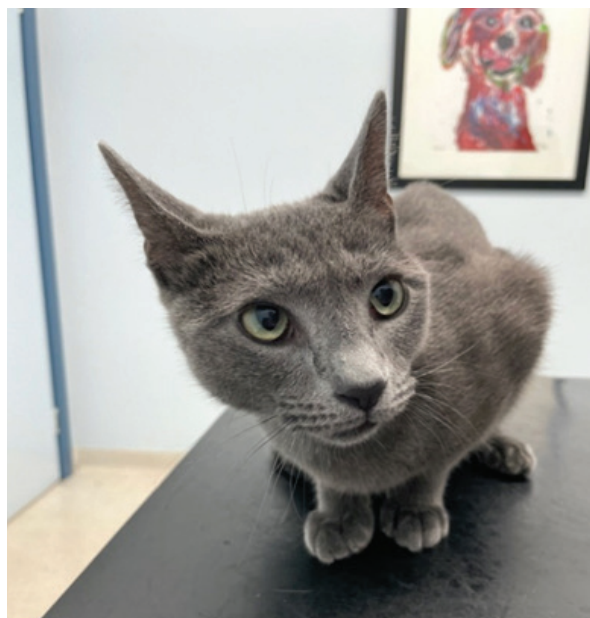

Figure 1. A 1-year-old M(N) cat who was originally diagnosed with lymphoma. The cat presented with enlarged mesenteric lymph nodes, enlarged liver, jaundiced, low albumin and high globulin and was subsequently diagnosed with dry FIP—now over 6 months in remission after completing 84 days of remdesivir. He was diagnosed based on his response to remdesivir.

Overview

Feline infectious peritonitis (FIP) is a fatal disease in cats whereby the relatively benign feline enteric coronavirus undergoes a mutation within a cat's own immune system—specifically within their macrophages—resulting in a disease known as FIP.

This mutation occurs in roughly 1 in 5,000 cats. FIP can be categorised broadly into two syndromes—wet FIP and dry FIP. Wet FIP is characterised by single or bi-cavitary effusions. Dry forms of FIP are much harder to diagnose as symptoms and changes on physical examination can be more subtle. Some of the more obvious symptoms that occasionally occur in cases of dry FIP include jaundice, enlarged mesenteric lymph nodes and uveitis—the disease often mimics lymphoma. FIP generally affects kittens and cats under the age of one; however, it can affect cats of all ages.

Diagnosing FIP

The diagnosis of FIP can at times be challenging. The classical symptoms of wet FIP are a high fever non-responsive to anti-microbials, single or bi-cavitary effusion, icterus and increased globulins. Cases will often also be anaemic, hypoalbuminaemic and have a significant neutrophilia. The same set of findings can be said for dry FIP in the absence of an effusion—however, with additional clinical signs which may include

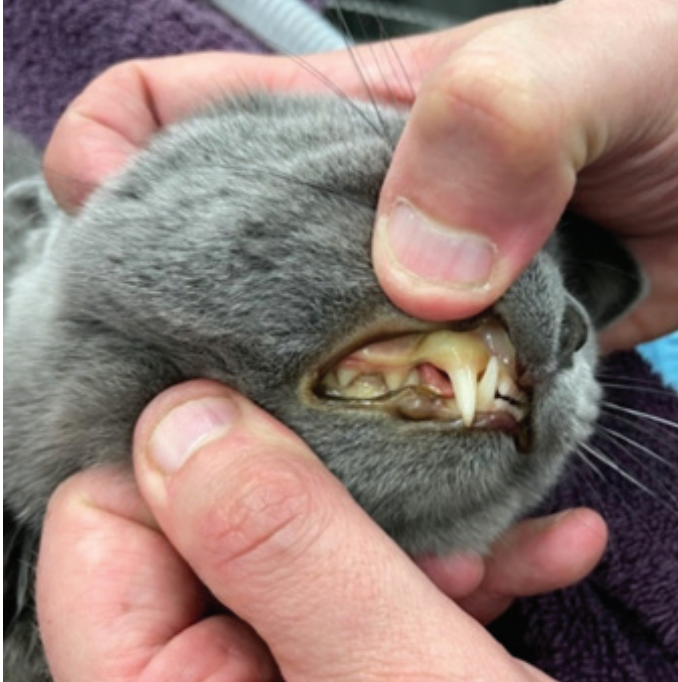

Figure 2. A cat with wet FIP presenting with severe jaundice and anaemia.

enlarged mesenteric lymph nodes, enlarged liver, changes to the kidneys on ultrasound, pulmonary granulomas, and central and ocular signs if there is a neurological or ocular component such as uveitis, blindness, and seizures.

Often a presumptive diagnosis of FIP can be made based on the above findings alone. Like any disease, it is up to an individual clinician as to the level of proof they require before commencement of treatment of FIP.

Further diagnostic testing can be carried out in an attempt to confirm the diagnosis of FIP, and some clinicians feel these tests need to be run prior to commencement of treatment. Perhaps a 'happy

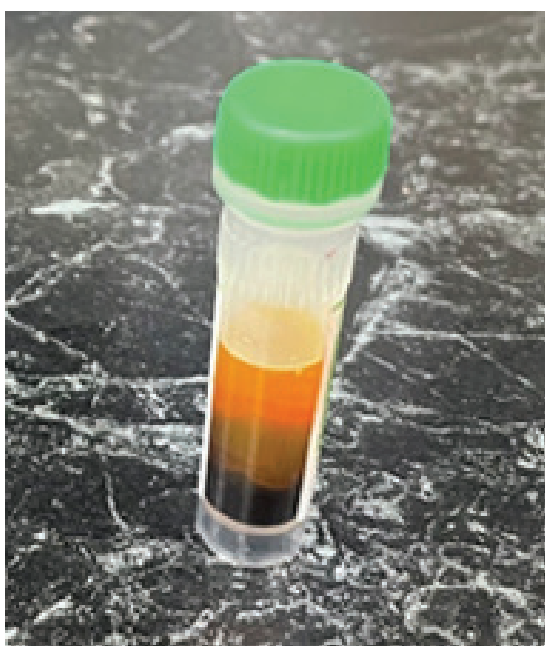


Figure 3. Icteric blood after centrifugation from the above jaundiced wet FIP cat. Note how anaemic the sample appears to be also.

medium' may be to make a presumptive diagnosis based on symptoms and laboratory findings above, then collect further samples for further analysis (outlined below) but commence treatment whilst waiting for results as some of these results can take up to 7 days.

It is important to note that there is no 100% accurate test for ruling in or out FIP and there will be times when it will come down to a clinician's judgement to diagnose FIP in a feline patient. Often it comes down to a clinician's level of confidence and experience treating FIP.

Further testing, when undertaken, can include:

- Coronavirus PCR on cavity effusion by IDEXX laboratories
- Immunofluorescence assay on cavity effusion by the University Veterinary Teaching Hospital Sydney (UVTHS)
- Immunocytochemistry on FNA samples of tissue aspirates by UVTHS, and
- Immunohistochemistry can be performed on tissue samples collected at ex-lap by UVTHS.

The Concord Veterinary Hospital Treatment Protocol

This article will discuss the use of a drug called remdesivir.

To recap—the common findings with both wet and dry FIP:

1. Uni or bicavitary effusion (Wet only)
2. High fever not responsive to antibiotics
3. Hyperglobulinaemia
4. Hypoalbuminaemia
5. Icterus
6. Non-regenerative anaemia
7. Neutrophilia

As per previous communication distributed by Richard Malik, one way to 'diagnose' FIP in cats, especially dry forms of FIP, is to trial patients on 3–4 days of remdesivir and if a rapid improvement in clinical signs is seen (reduction in mesenteric lymph node size, resolution of fevers, regaining of appetite) then the diagnosis of FIP is essentially confirmed.

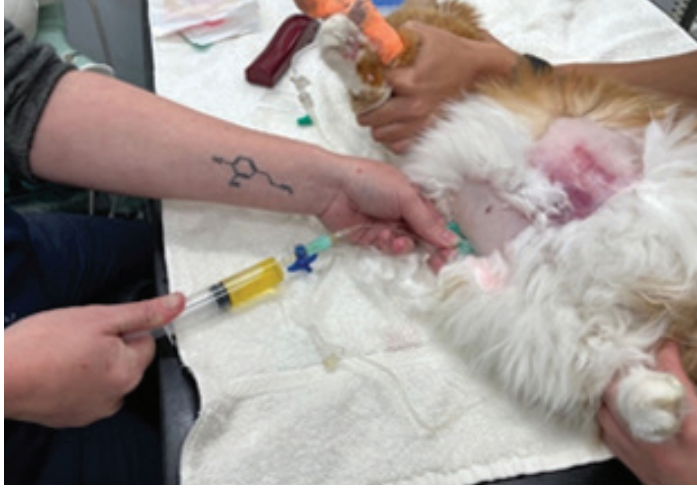

Figure 4. Collecting abdominal fluid from a wet FIP patient to submit a sample for immunofluorescence assay to VPDS, SSVS.

What is Remdesivir?

Remdesivir is a broad-spectrum antiviral developed by the pharmaceutical company Gilead. Remdesivir was originally developed to treat Hepatitis C and Ebola Virus; however, it was fast-tracked and given approval in many countries worldwide for the treatment of COVID-19. Its use now in COVID-19 patients is controversial; however, it is showing amazing promise for the treatment of FIP in cats.

Treatment with Remdesivir

Treatment with remdesivir is for 84 days by subcutaneous injection, so it requires a committed owner or a sympathetic veterinarian geographically close by. Remdesivir can be sourced readily from BOVA Compounding Pharmacy who ship Australia-wide normally overnight. The cost of the drug is significant; the vials are 100mg/vial at \$275/vial inclusive of GST. The final concentration is 10mg/mL. Needless to say—treatment of FIP by an owner takes a lot of financial and emotional commitment.



Figure 5. A F(S) Bengal cat with ocular and central FIP before treatment with remdesivir. Note the dilated pupils. This cat was centrally blind prior to treatment.

The First 3 to 4 days

The earlier treatment is commenced, the better the outcome—and *this cannot be overstated*. There are two options for commencing treatment and like most things in life it often comes down to budget.

1. Subcutaneous Injections

If a patient is stable and eating—subcutaneous injections can be commenced at a dose rate of 10mg/kg and the patient checked daily for the first 3–4 days. This is a perfectly acceptable routine for a well-hydrated patient who is eating, and is the more financially sustainable option.

2. The intravenous Route

If a patient is unwell, or neurological or ocular FIP is suspected, then they should be hospitalised, placed on intravenous fluids, run at a quarter to a half maintenance rates (Hartmann's or similar is fine). The reason for such a low rate will become clear shortly, and remdesivir administered SLOW IV (over 10 minutes is fine) for 3–4 days. We have found if you can maintain your catheter to a fourth day it is great to get a fourth intravenous dose into your patient; however, if there is pain at the cannula site or thrombophlebitis, then 3 days is fine.

The downside to administering remdesivir intravenously is obviously having to hospitalise the patient, the added expense to the owner which is not insignificant and also there is an increased risk (10% risk) of developing or worsening of a pleural effusion with the use of intravenous remdesivir,



Figure 6. The same Bengal some 4 – 6 weeks later after treatment with remdesivir with a normal ocular exam and apparent full vision.

mostly in wet forms, which then requires close monitoring by either regular thoracic radiography or T-Fast ultrasonography daily or twice daily (we prefer twice daily).

The benefits of intravenous remdesivir are you get a high anti-viral dose to target the virus for the initial 3–4 days, you get to observe your patient and more often than not get to see the fever break in front of your eyes and to see a near moribund patient 'come back to life' and show signs of improvement daily!

Obviously, this is a conversation to be had with each individual owner and for the clinician to make on a case-by-case basis. See below for other considerations before deciding which patients would or would not benefit from intravenous remdesivir therapy.

Cats receiving intravenous remdesivir do not need to be in a 24-hour facility—remdesivir could be administered intravenously in the mornings so a clinician then has the whole day to observe their patient. We have also heard examples of veterinary hospitals administering the intravenous remdesivir and then sending the patient home for the night with the indwelling intravenous catheter in place so the owner can monitor the cat for the night in case of emergency and to keep costs down.

Days 5 to 84

Remdesivir needs to be given at a dose of 8–10mg/kg subcutaneously once daily for 84 days in total. We would encourage dry forms to be dosed at 10mg/kg (ocular and neurological forms often require 15mg/kg) and wet forms 8mg/kg. In our experience there is a tendency for vets to reduce the dose of remdesivir prematurely. **Do not dose to lean body mass or try and assume what a kitten might weigh without its effusion**—kittens metabolise drugs faster so need a higher dose. Simply dose them for their weight—keep it simple.

Do things to encourage success in your patients for injections. For example; remdesivir is stored in the fridge. However, it is fine for it to come to room temperature before injection; this will help minimise the pain with the injection. We have found 22G needles minimise pain for injection; however, some cats prefer 23G or 25G—it really is a game of trial and error.

Some cats need to come into the vet every day for their injection. Even this shows serious commitment by the owner! Furthermore, some patients require the use of buprenorphine prior to their injection, especially as they approach the end of the course of their 84 days. Gabapentin orally prior to injection has been trialled with less success but is still worth a try in some cases.

It is worth noting at this point we are often dealing with kittens here – so ensure they are being weighed regularly and their dose of remdesivir is being adjusted upwards accordingly to 8–10mg/kg.

Monitoring

Do not fall into the trap of doing blood work on days 1–3 after commencing treatment—nothing will have changed.

Once again, the bloods that are performed depend on the financial limitations of your client. Ideally, we like to perform a CBC and Biochemistry panel (including bilirubin and globulins) at week 4, week 8 and week 12. We are looking for resolution of anaemia, reduced neutrophils, normal albumin and globulin and normal bilirubin.

In theory you could also simply perform a PCV, TPP and a globulin level. This will give you an idea of the anaemia, the colour of the serum to check if your patient is still jaundiced, the albumin and the globulin level by simple calculation.

When Does Treatment End?

We get asked this question a lot.

Treatment ends when:

1. ALL blood parameters are WELL within normal limits including globulins.
2. All effusions are absent.
3. Lymph nodes are normal
4. There are no central/ocular signs.

At this point, we call them 'cured'.

But How Long Do They Last and How Many Have Died?

It is still extremely early days. The answer is we simply do not know. We estimate the efficacy of remdesivir to be 80–95%. Wet has a better prognosis than dry for example, and neurological has a worse prognosis than non-neurological.

We will only comment on our cases as we have developed our regime. Of some 20 cases—1 case was lost as it presented moribund and unable to be saved, 1 case was lost that had concurrent FIV, the FIP was 'cured'; however, the cat went on to

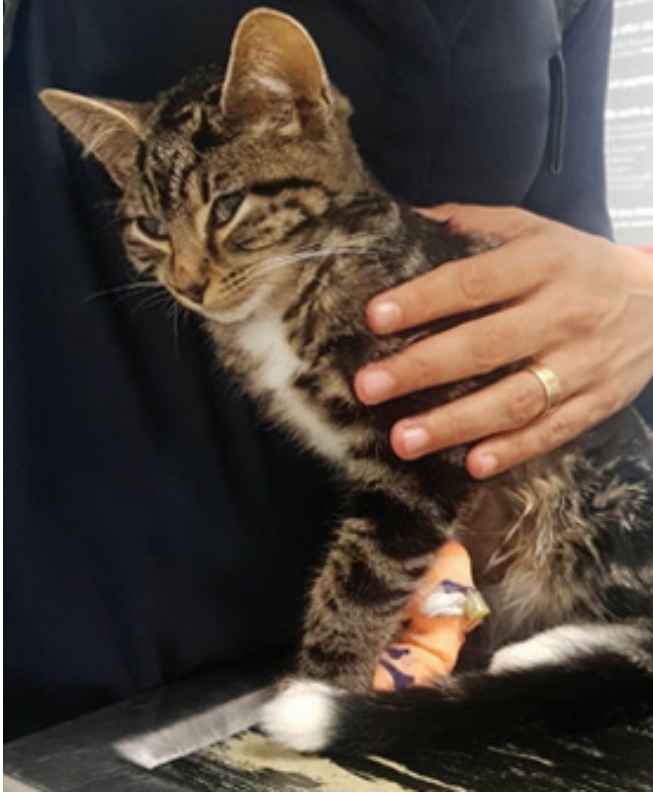

Figure 7. A M(N) 12-week-old domestic shorthair with dry FIP – they generally just look ‘poorly’ with a fever that persists.



Figure 8. The same domestic shorthair cat with dry FIP just 4 weeks into treatment with remdesivir.

develop mediastinal lymphoma, and 1 kitten was put to sleep for presumed septicaemia. The other cases are at various stages of remission or still in treatment.

It is worth noting—we have 2 cases currently, both dry—where we have been unable to reduce the globulins to a normal level beyond 84 days, so we have had to increase the dose to 15mg/kg, and both are well over 110 days treatment but are doing well. The likely cause for both of these prolonged and ‘unsuccessful-so-far’ cases has been a reduction in dose from 10mg/kg to 6mg/kg. **We would advise against this—especially in dry forms.**

10 Important Points About the Use of Remdesivir:

- 1 **THE MOST IMPORTANT POINT TO NOTE:** 10% of cats receiving intravenous remdesivir can develop pleural effusions—especially wet form. Therefore, cats receiving intravenous remdesivir need to have serial radiographs and/or skilled T-Fast ultrasonography on a daily or bi-daily basis. Pleural effusions are more likely if a clinician pushes the intravenous fluid administration beyond maintenance—we prefer to keep the fluid rate below half maintenance.
- 2 Many patients will become quiet for 1–3 hours after receiving remdesivir intravenously—the exact mechanism is unknown but do not be too alarmed if this occurs.
- 3 Wet cases: the ABDOMINAL effusion will often get worse before it gets better. This is a good sign. It is recommended to NOT drain the abdominal fluid unless to get diagnostic samples or for urgent therapeutic reasons (e.g. if dyspnoea is severe due to pressure onto the diaphragm).
- 4 Globulins will often go up at the first blood test before they begin to come down. Do not get disheartened.
- 5 Many vets are concerned about the reports of elevations in kidney and liver parameters with the use of remdesivir. There have been a few reports of elevations in SDMA and occasional reports of elevation in ALT with doses of remdesivir as high as 15mg/kg that resolved once the dose was resumed to normal. The authors have had 2 cats on 15mg/kg of remdesivir and has not personally seen elevations in ALT (but have not checked SDMA for various reasons).
- 6 Antibiotics: Often FIP cats have comorbidities with infections which require treatment with antibiotics. Infections such as Mycoplasma are common. Antibiotics such as doxycycline are often a good choice. Other antimicrobials—if indicated—do not appear to be contraindicated.
- 7 NSAIDs to bring fevers down are often NOT required with the use of remdesivir.
- 8 The concurrent use of corticosteroids with remdesivir is not strictly contraindicated; however, it is not recommended. If your patient

is on corticosteroids we would recommend weaning them as quickly as is safe to do so.

9 Remdesivir can occasionally sting as an injection, so our clients need our help with respect to teaching them how to administer the drug and pointers on how to minimise the sting (needle choice size, allowing the drug to come to room temperature prior to injection, utilising medications such as buprenorphine prior to injection). The drug itself doesn't appear painful—it is the repeated injections and the amount of liquid that needs to be injected daily. weaning them as quickly as is safe to do so.

10 Often it can be beneficial to a patient to commence a treatment trial of remdesivir to see if a presumptive diagnosis can be made of FIP or whilst waiting for further diagnostics to return from the lab.■



eBook download

C&T 5883 Feline Infectious Peritonitis (FIP)—Now a treatable disease.

Jane Yu, Merran Govendir, Sally J Coggins & Jacqueline M. Norris, Issue 303 June 2021.

PLEASE CONTACT US if you'd like to be a part of these trials

Two clinical trials for naturally occurring FIP infected cats have commenced at the Sydney School of Veterinary Science at The University of Sydney and are recruiting Australia-wide:

- one looking at mefloquine, with and without interferon
- the other looking at Remdesivir

And/Or you need advice for a suspected or confirmed FIP Case

Jacqui Norris at

jacqui.norris@sydney.edu.au

Sally Coggins at

sally.coggins@sydney.edu.au